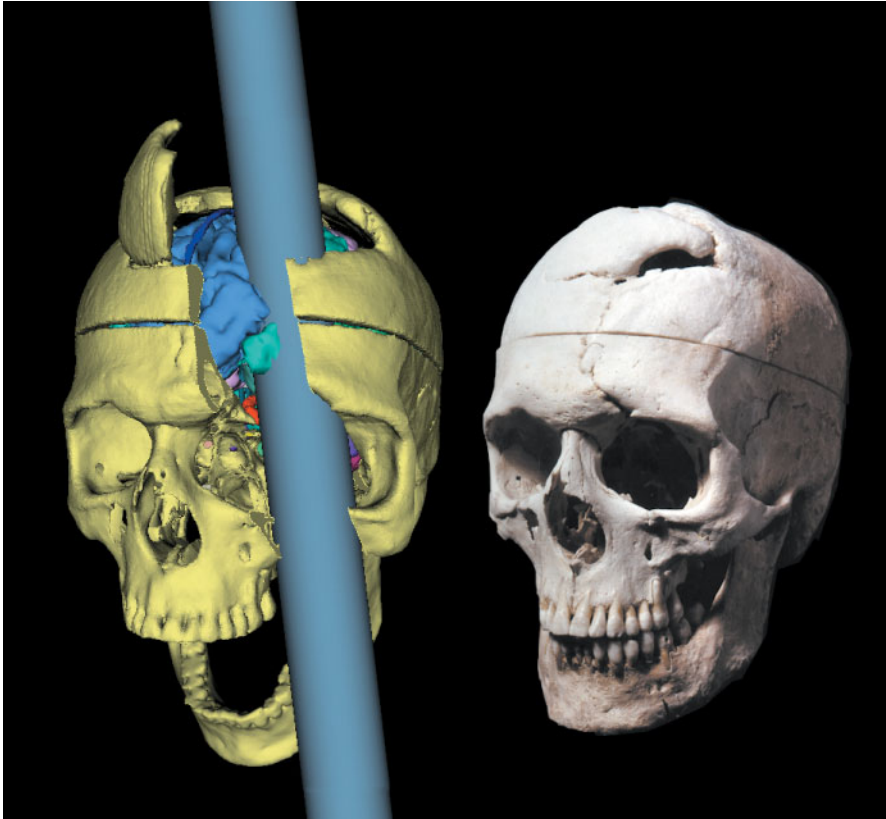


The Tale of Phineas Gage, Digitally Remastered



Peter Ratiu, M.D.
Ion-Florin Talos, M.D.

Brigham and Women's Hospital
Boston, MA 02115

ON SEPTEMBER 13, 1848, WHILE USING A TAMPING IRON TO PACK EXPLOSIVE INTO A ROCK, PHINEAS GAGE, a 25-year-old construction foreman, triggered an uncontrolled explosion that propelled the tool (which measured 3 ft 7 in. in length and 1.25 in. in diameter) through his left cheek and head. He regained consciousness within minutes and was immediately transported back to his boardinghouse while seated in a horse cart. Permanent personality changes and left-sided amaurosis of delayed onset were the long-term consequences. We generated three-dimensional computer reconstructions of the original skull from a thin-slice computed tomographic image (Video Clip 1) and of the tamping iron. With the use of a nonaffine algorithm, a three-dimensional model of a normal brain generated by magnetic resonance imaging was registered with the skull model. The radiologic findings were correlated with the clinical data recorded by the original physician in charge of the case, John Martyn Harlow. We concluded that since the size of the defect in the bone at the entry site in the base of the skull was half the size of the projectile's diameter, and given the pattern of the fracture lines, the zygomatic process of the left maxilla must have fractured in continuation with the orbit. This, in turn, allowed the left side of the face to swing laterally, thus permitting the passage of the projectile (Video Clip 2: the left panel shows the reconstruction of the injury as viewed from the outside; the right panel shows the same sequence as viewed from the inside of the skull). The brain injury must have been limited to the left frontal lobe and spared the superior sagittal sinus. (A lesion in the superior sagittal sinus would have posed a double threat to the life of Gage by causing a massive hemorrhage, an air embolism, or both. Obviously, neither occurred.) The skull specimen was provided for scanning by the Countway Library of Medicine, Boston.

Copyright © 2004 Massachusetts Medical Society.